



2020

Effects of Different Occlusion Setups with a Surgery-First Approach and Simulated Presurgical Orthodontics on the Mandibular Position in Skeletal Class III Malocclusion

Gloria Shih-Wen Fan

YueXiang Dental Clinic, Taoyuan, Taiwan; Graduate Institute of Dental and Craniofacial Science, Chang Gung University, Taoyuan, Taiwan

Yu-Chih Wang

Department of Craniofacial Orthodontics, Chang Gung Memorial Hospital, Taipei, Taiwan; Craniofacial Research Center, Chang Gung Memorial Hospital, Linkou, Taiwan

Chiung Shing Huang

Department of Craniofacial Orthodontics, Chang Gung Memorial Hospital, Taipei, Taiwan; Graduate Institute of Dental and Craniofacial Science, Chang Gung University, Taoyuan, Taiwan; Craniofacial Research Center, Chang Gung Memorial Hospital, Linkou, Taiwan

Ellen Wen-Ching Ko

Department of Dentistry, Chang Gung Memorial Hospital, Taipei, Taiwan, ellenko.wc@msa.hinet.net

Follow this and additional works at: <https://j.tjo.org.tw/tjo>



Part of the [Orthodontics and Orthodontology Commons](#)

Recommended Citation

Fan, Gloria Shih-Wen; Wang, Yu-Chih; Huang, Chiung Shing; and Ko, Ellen Wen-Ching (2020) "Effects of Different Occlusion Setups with a Surgery-First Approach and Simulated Presurgical Orthodontics on the Mandibular Position in Skeletal Class III Malocclusion," *Taiwanese Journal of Orthodontics*: Vol. 32 : Iss. 1 , Article 1.

DOI: 10.30036/TJO.202003_32(1).0001

Available at: <https://j.tjo.org.tw/tjo/vol32/iss1/1>

This Original Article is brought to you for free and open access by Taiwanese Journal of Orthodontics. It has been accepted for inclusion in Taiwanese Journal of Orthodontics by an authorized editor of Taiwanese Journal of Orthodontics.

Effects of Different Occlusion Setups with a Surgery-First Approach and Simulated Presurgical Orthodontics on the Mandibular Position in Skeletal Class III Malocclusion

Cover Page Footnote

We express our gratitude to our colleague, Mr. Cheng-Wei Chen, for his assistance in the superimposition and simulation techniques.

EFFECTS OF DIFFERENT OCCLUSION SETUPS WITH A SURGERY-FIRST APPROACH AND SIMULATED PRESURGICAL ORTHODONTICS ON THE MANDIBULAR POSITION IN SKELETAL CLASS III MALOCCLUSION

Gloria Shih-Wen Fan,^{1,3}

Yu-Chih Wang,^{2,4}

Chiung Shing Huang,^{2,3,4}

Ellen Wen-Ching Ko^{2,3,4}

¹YueXiang Dental Clinic, Taoyuan, Taiwan

²Department of Craniofacial Orthodontics, Chang Gung Memorial Hospital, Taipei, Taiwan;

³Graduate Institute of Dental and Craniofacial Science, Chang Gung University, Taoyuan, Taiwan;

⁴Craniofacial Research Center, Chang Gung Memorial Hospital, Linkou, Taiwan

Purpose: The purposes of this study were to compare the occlusion designs implemented for the surgery-first approach (SFA) and the resultant mandibular movements by different orthodontists, as well as to investigate whether presurgical dental alignment is associated with mandibular positioning.

Methods: This prospective study included 15 patients with skeletal Class III malocclusion who underwent orthognathic surgery through the SFA. Three orthodontists designed an occlusion setup for each case, which were assigned as SFA groups. The same group of patients, who received simulated presurgical orthodontics (SPO) through a virtual setup, composed the control group. The postoperative dental relationship and resultant mandibular movements were compared within the SFA groups and also with the SPO group. Three-dimensional skeletal and dental variables were measured and compared using simulation software.

Results: No significant differences in the mandibular movement and dental relationship were observed among the three SFA groups. A significant increase in the vertical dimension (VD) of the posterior mandible was observed in the SFA groups, whereas it was reduced in the SPO group.

Conclusion: Orthodontists with different occlusion setup details had similar design strategies and were able to manage the SFA with compatible outcomes. Surgical orthodontic treatment without preoperative dental alignment results in an increased VD in the posterior mandible during surgery. (*Taiwanese Journal of Orthodontics*. 32(1): 4-16, 2020)

Keywords: orthognathic surgery; surgery-first approach; dental occlusion setup; simulated presurgical orthodontics

Received: February 11, 2020 Revised: March 19, 2020 Accepted: March 20, 2020

Reprints and correspondence to: Dr. Ellen Wen-Ching Ko, Department of Dentistry, Chang Gung Memorial Hospital, Taipei, Taiwan
6F 199 Tung-Hwa North Rd. Taipei 105, Taiwan

Tel: +886-2-27135211 ext. 3533 Fax: +886-2-25148846 E-mail: ellenko.wc@msa.hinet.net

INTRODUCTION

Conventional surgical orthodontic treatment requires preoperative orthodontic preparation involving dental alignment, incisor decompensation, and arch coordination, all of which aim to eliminate interferences that may hinder a stable postsurgical occlusion or optimal skeletal correction during surgery.^{1,2} Although this approach ensures a stable early surgical occlusion setup, the procedure is lengthy and inefficient, in addition to temporarily aggravating the facial profile and oral function.

To overcome the mentioned limitations, a surgery-first approach (SFA) that obviates presurgical orthodontic treatment, in contrast to the conventional orthodontic-first approach, was proposed. The SFA has several advantages; such as main complaints can be resolved at an early treatment stage and that the total treatment duration is considerably shortened because (1) presurgical orthodontic treatment is not required, (2) dental decompensation is more efficient after the correction of skeletal discrepancies, and (3) faster tooth movement benefits from a rapid acceleration phenomenon immediately after surgery.^{3,4} Currently, the SFA has gained popularity, and several studies have revealed that for skeletal Class III surgical correction, the long-term occlusal outcomes of maxillofacial and dental relationships did not significantly differ between the SFA and the orthodontic-first approach in transverse, vertical, and sagittal dimensions.⁵⁻⁷

Although positive results supporting the use of the SFA have been shown by clinical evidence, most clinicians still lack the confidence to apply the SFA. This is because surgical positioning of the mandible is not only determined by the position of the maxilla but is also largely affected by dental occlusions. In addition, a stable occlusion is a prerequisite for a predictable postoperative result, and when a stable postsurgical occlusion is not attainable with the SFA, the main concerns are postoperative instability and unpredictable outcomes.^{3,8}

Furthermore, different orthodontists may plan different postoperative occlusal relationships to avoid interferences within a single case.

To counterbalance these two approaches, a modified method involving minimal presurgical orthodontics (MPO),^{9,10} also called the modified conventional approach,⁷ has been proposed as a solution. This minimal presurgical preparation is performed to minimize occlusal interference during surgery by preoperative preliminary alignment. Because complete decompensation is not the desired outcome during this stage, it usually lasts less than 6 months. According to our review of the relevant literatures, only one study compared the results of MPO and the SFA and focused on postsurgical dental and skeletal changes and stability.⁷ Moreover, the outcome of this study was assessed in two dimensions. The effect of presurgical alignment on the mandibular positioning during surgery, which is one of the main concerns of clinicians, has yet to be evaluated.

The purposes of the present study were to (1) compare different orthodontists' occlusion designs for correcting skeletal Class III deformities through the SFA with the resultant mandible movement pattern during surgery in 3D and (2) investigate whether presurgical dental alignment influences surgical mandibular positioning.

MATERIALS AND METHODS

Patients

This prospective cohort study consisted of 15 adult patients with skeletal and dental Class III malocclusion ($ANB < 0$) who had undergone orthodontic treatment and two-jaw surgery (Le Fort I osteotomy and bilateral sagittal split osteotomies) through the SFA at Chang Gung Memorial Hospital during 2014–2015. These orthodontic treatments did not involve tooth extraction, except for the third molars. Patients with syndromic craniofacial deformities, cleft lip or palate, a history of trauma, a

history of surgical correction, or a surgical plan involving multiple-pieces osteotomies were excluded. Cases involving extraction or multiple-pieces osteotomies were excluded because they may introduce new variables such as extraction space management and post-operative skeletal instability, which affect dental and skeletal outcomes. This study followed the World Medical Association Declaration of Helsinki on medical protocol and ethics. It was approved by the Institutional Review Board of Chang Gung Memorial Hospital, and all participants signed an informed consent agreement (IRB No. 102-5936A3).

Data collection

This study collected and investigated the patients' presurgical orthodontic records including clinical photographs, cone-beam computed tomography (CBCT) images, dental models with bite records, and radiographs (panoramic and cephalometric images). Three orthodontists with different levels of experience in surgical orthodontics, hereafter referred to as orthodontists A, B, and C, were requested to set up and design a postoperative occlusion for each patient. The occlusion plans obtained from orthodontists A, B, and C were designated as occlusions A, B, and C, respectively. The mentioned clinical records were provided as references to each orthodontist for occlusion planning.

Simulated surgical mandibular movement

CBCT images of all patients were obtained using an i-CAT CBCT scanner (Imaging Sciences International, Hatfield, PA, USA) with a voxel resolution of 0.4 mm in the upright position. DICOM files of the CBCT images were imported into the software program, SimPlant O&O version 3.0 (Materialise, Leuven, Belgium). Patients were requested to undergo the scan with a natural head posture and centric occlusion.

The constructed composite craniofacial 3D virtual models were set up by replacing the dentition with dental model scans. The simulated surgical cuts in the BSSO process were performed on the virtual models. The STL files of presurgical occlusion along with postsurgical

occlusions A, B, and C of each case were imported into Simplant O&O (Materialise, Leuven, Belgium). The simulated surgical mandibular movements were obtained through the registration of occlusions A, B, and C to the distal segment in simulated BSSO. To focus on the postoperative position of the mandible engendered by the fixed occlusion, the maxilla was maintained in its presurgical position. The corresponding mandibular positions generated were denoted as mandibles A, B, and C.

Simulated presurgical orthodontics

For the control group, presurgical records were obtained from the same group of patients. The surgical occlusions were set up after digital virtual dental alignment, a process called simulated presurgical orthodontics (SPO).

To simulate the presurgical dental alignment, all the dental casts were scanned and digitalized with the 3Shape Orthodontics System™ dental surface scanner (Copenhagen, Denmark). The 3Shape OrthoAnalyzer™ software program (v1.5.1.3, Copenhagen, Denmark) was used in the SPO process. First, an individualized ideal arch form for each patient was constructed with a minimal change in the mandibular intercanine and intermolar widths. The SPO process involved aligning the teeth to the ideal arch form based on the concept of Angle's line of occlusion,¹¹ followed by dental leveling, which was primarily executed through tipping (Figure 1). Subsequently, the mandibular arch was moved to articulate the maxillary arch for establishing a bilateral Class I molar relationship with the tripod occlusion to simulate the postoperative occlusal relationship after orthodontic preparation. The prepared dentition was later reverted to its original dentition through superimposition on the dental base by using Geomagic studio v12 (North California, USA). The new occlusion generated and the resultant mandibular position were named as occlusion D and mandible D, respectively.

3D measurements

Four reference planes were used for measurements. The Frankfort-horizontal plane (FHP) is formed by the

bilateral orbitales and the midpoint of the porion. The midsagittal plane (MSP) is perpendicular to the FHP and passes through the nasion and basion (Ba). The basion plane (BaP) is the coronal plane perpendicular to the MSP and FHP and passes through the Ba. The upper occlusal plane is formed by the midpoint of the incisal edges of the maxillary central incisors and mesiobuccal cusps of the bilateral upper first molars. The skeletal reference planes used for measurements in the present study are demonstrated in

Figure 2, and the definitions of all measurement variables are presented in Table 1. Occlusions A, B, and C were compared to evaluate the dental relationship of the setups. Mandibles A, B, and C were compared to analyze the resultant mandible movement from different occlusions. To compare the outcomes of the SFA setup proposed by each orthodontist with that of the SPO group, mandibles A, B, and C were compared with D. The sequence of processes is shown in the schematic in Figure 3.

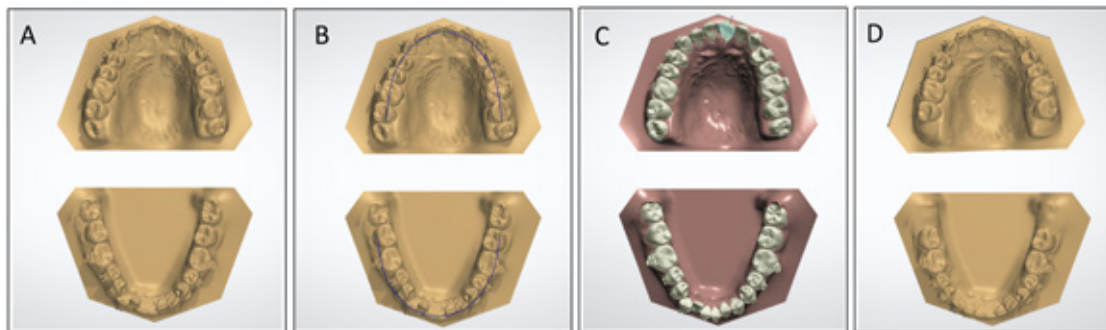


Figure 1. Steps of the simulated presurgical orthodontics (SPO). A, Preoperative casts were scanned and imported into 3Shape OrthoAnalyzer™ software; B, an individualized ideal arch form was constructed for each patient with a minimal change in the mandibular intercanine and intermolar widths; C, teeth were aligned and leveled onto the ideal arch form on the basis of Angle's line of occlusion concept, primarily by tipping; D, completion of the SPO and moving the mandibular arch to articulate with the maxillary dentition.

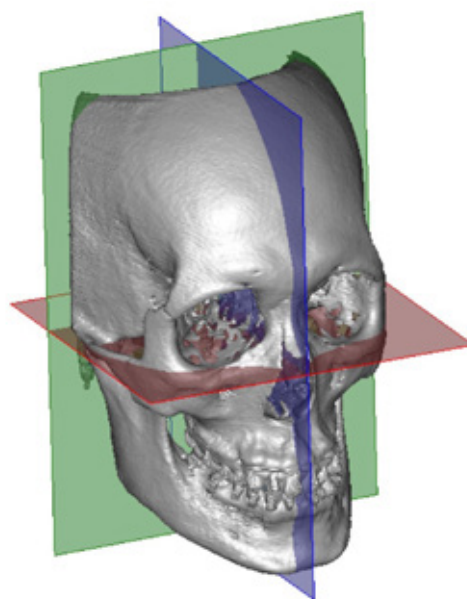


Figure 2. Skeletal reference planes for 3D measurements. Green, basion plane (BaP); red, Frankfort-horizontal plane (FHP); blue, midsagittal plane (MSP).

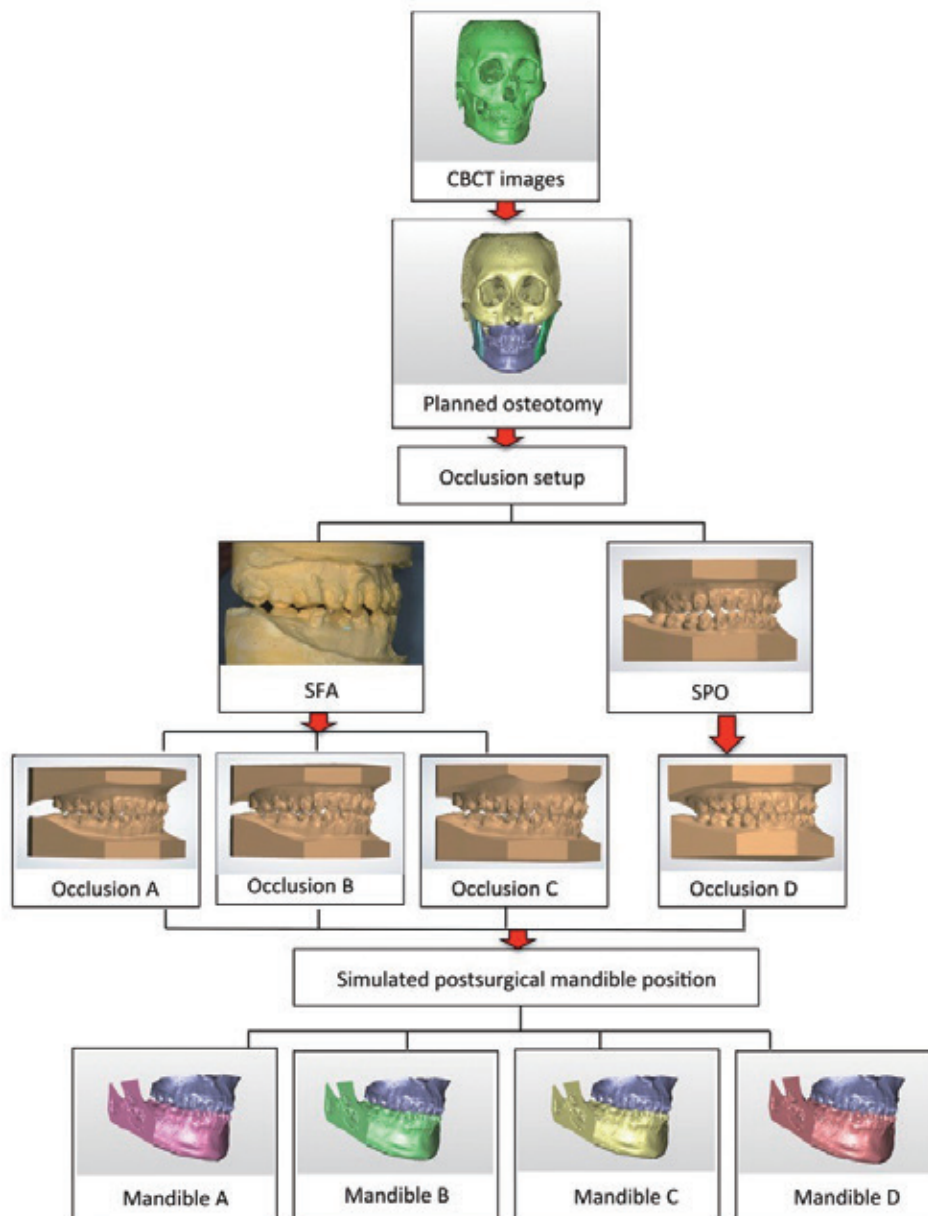


Figure 3. Experimental design. Simulated BSSO was performed on the constructed composite craniofacial 3D virtual models. The occlusion setups were obtained for the SFA (A, B, and C design) groups and the SPO group. The simulated surgical mandible movements were obtained by registration of occlusions A, B, and C to the distal segment of BSSO. For SPO, the dentition alignment and occlusion were simulated (occlusion D) and reverted to the original craniofacial model to generate the resultant mandible D.

Table 1. Definitions of the measurements

Measurement		Definition	Sign
Dental relationship	Overjet (mm)	The distance between U1 and L1 incisal edges parallel to UOP	+: U1 in front of L1 - : U1 behind L1
	Overbite (mm)	The distance between U1 and L1 incisal edges parallel to BaP	+: Overlapped - : No overlap
	Canine relationship (mm)	The horizontal distance between U3 cusp tip to the embrasure between L3 and L4 parallel to FHP	+: U3 in front of L3, Class II - : U3 behind L3, Class III
	Molar relationship (mm)	The horizontal distance between U6 mesiobuccal cusp to L6 buccal groove parallel to FHP	+: Class II - : Class III
	Posterior open bite (mm)	The vertical distance between U6 mesiopalatal cusp to L6 central fossa parallel to BaP	Amount, all positive
	Lower midline deviation (mm)	The distance between lower midline to MSP	+: Undercorrection - : Overcorrection
Mandible movement	Chin deviation correction (mm)	The change of distance between Pog to MSP from presurgical to postsurgical position	+: Increase in deviation - : Reduction in deviation
	Setback amount at Bo (mm)	The distance between presurgical and postsurgical Bo (average of BoL and BoR) parallel to MSP	Amount, all positive
	Setback amount at Pog (mm)	The distance between presurgical and postsurgical Pog parallel to MSP	Amount, all positive
	Anterior VD change (mm)	The difference of Pog to FHP between presurgical and postsurgical position	+: Increase - : Decrease
	Posterior VD change (mm)	The difference of Bo (average of BoL and BoR) to FHP between presurgical and postsurgical position	+: Increase - : Decrease

U1, upper central incisor; L1, lower central incisor; U3, upper canine; L3, lower canine; L4, lower first premolar; U6, upper first molar; L6, lower first lower; UOP, upper occlusal plane; FHP, Frankfort horizontal plane; BaP, Basion plane; MSP, midsagittal plane; VD, vertical dimension; Bo, border point at which the osteotomy line intersects with the lower border of the distal segment; BoL, Bo left; BoR, Bo right.

Statistical analyses

Statistical analyses were performed using SPSS 17.0 (Chicago, IL, USA). The measurements of the dental relationship and mandible movement in mandibles A, B, and C were compared using the Kruskal–Wallis test. Mandible movement between the SFA and SPO groups was compared using the Mann–Whitney test. The differences were considered significant at $P < .05$.

Error test

We randomly selected 5 cases from the study sample. Landmarks in their CBCT images were re-recognized at a 1-month interval. A reproducibility test was conducted by comparing the original and repeated measurements using Dahlberg's formula ($\sqrt{\sum d^2/2n}$), where d is the difference between the two measurements and n is the number of paired double measurements. The method error of the measurement ranged from 0.03 to 0.85 mm.

RESULTS

The study sample consisted of 7 men and 8 women aged 19–38 years (mean, 23.0 ± 5.3 years). Among these 15 skeletal Class III deformities cases, 6 were asymmetric (chin deviation > 4 mm), and 5 cases had an anterior open bite ($OB < 0$).

For the surgical occlusion setup, there was no significant difference in the postoperative dental relationship (Table 2). The occlusion setup indicated an overbite ranging from -3.6 to 3.41 , overjet ranging from 2.32 to 8.56 ; and Class II canine relationship, with a discrepancy of 0.54 – 7.23 mm. Regarding the molar relationship, a few cases had mild Class III molars (maximal discrepancy, 1.18 mm) and most cases had Class II molars (maximum at 5.3 mm). In addition, the posterior open contact at the first molar ranged from 0.49 to 5.31 mm. Occlusion B tended to show a smaller overjet and overbite along with a more Class I buccal relationship with a lower extent of posterior open bite than that of the other 2 occlusions (A and C); however the differences

were not significant. ($P > .05$)

For the simulated mandibular movements during BSSO, no statistically significant difference was observed in the mandible movement among the three setups (Table 3). Furthermore, the amounts of chin deviation correction, mandibular setback, and vertical dimension (VD) change among the three groups varied; however, the differences were not significant. An increased overbite and posterior open bite were associated with a greater reduction in the anterior VD and a greater increase in the posterior VD, respectively.

No statistically significant differences were detected in the mandibular position between the SFA and SPO groups, except for a posterior VD change between each SFA group and SPO group and a sagittal change of the pogonion between mandible C and D (Table 4). All SFA groups showed a significantly increased VD in the posterior mandible, whereas the SPO group showed decreased posterior VD. Mandible C had a lower mandibular setback amount at the anterior part than did mandible D.

Table 2. Comparison of the dental relationship with the occlusion setups A, B, and C

Measurement	A				B				C				p
	Mean	SD	Min	Max	Mean	SD	Min	Max	Mean	SD	Min	Max	
Overbite (mm)	1.14	0.96	-1.12	2.61	1.01	1.55	-3.60	3.03	1.72	1.18	-0.04	3.41	0.447
Overjet (mm)	4.43	1.43	2.38	8.03	4.14	1.67	2.32	8.32	4.58	1.62	2.60	8.56	0.318
Canine relationship (mm)	3.72	1.10	1.81	5.30	3.44	1.49	1.10	7.29	3.82	1.59	0.54	7.53	0.546
Molar relationship (mm)	1.50	1.51	-1.14	4.50	1.20	1.74	-0.95	4.81	1.71	1.88	-1.18	5.30	0.630
Post open bite (mm)	2.34	1.14	0.63	5.31	2.07	0.92	0.49	4.58	2.60	0.96	1.17	4.68	0.240
Lower midline deviation (mm)	0.42	0.61	-0.34	2.07	0.51	0.72	-0.97	1.82	0.58	0.65	-0.81	1.83	0.439

Table 3. Comparison of the mandibular movement with occlusion setups A, B, and C

Measurement	A		B		C		p
	Mean	SD	Mean	SD	Mean	SD	
Chin deviation correction (mm)	-1.80	2.51	-1.78	2.67	-2.10	2.44	0.868
Setback amount at Bo (mm)	3.51	3.22	3.84	1.81	2.69	2.98	0.570
Setback amount at Pog (mm)	2.64	3.78	3.08	1.90	1.59	3.61	0.429
Anterior VD change (mm)	-1.82	2.20	-1.78	2.30	-2.45	2.68	0.615
Posterior VD change (mm)	1.25	1.55	1.00	1.19	1.98	1.40	0.091

VD, vertical dimension; Bo, border point at which the osteotomy line intersects with the lower border of the distal segment; Pog, pogonion.

Table 4. Comparison of mandibles A, B, C, and D

Measurement	A		B		C		D		p		
	Mean	SD	Mean	SD	Mean	SD	Mean	SD	A vs. D	B vs. D	C vs. D
Chin deviation correction (mm)	-1.80	2.51	-1.78	2.67	-2.10	2.44	-1.66	3.06	0.95	0.90	0.678
Setback amount at Bo (mm)	3.51	3.22	3.84	1.81	2.69	2.98	4.71	2.50	0.42	0.33	0.074
Setback amount at Pog (mm)	2.64	3.78	3.08	1.90	1.59	3.61	4.31	2.62	0.33	0.237	0.049*
Anterior VD change (mm)	-1.82	2.20	-1.78	2.30	-2.45	2.68	-2.03	2.16	0.69	0.58	0.772
Posterior VD change (mm)	1.25	1.55	1.00	1.19	1.98	1.40	-1.41	1.58	0.000***	0.000***	0.000***

VD, vertical dimension

*P < 0.05, ***P < 0.001

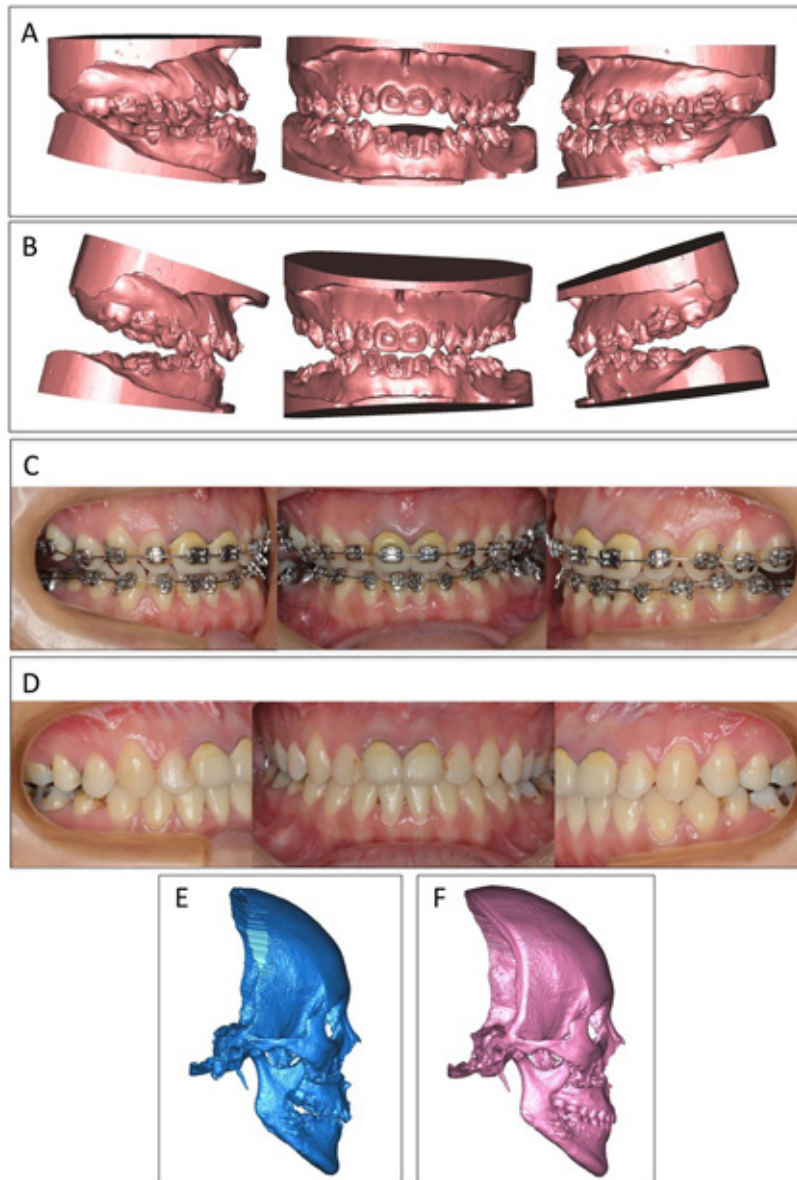


Figure 4. Occlusion setup and postoperative occlusion correction in an extreme case undergoing the SFA. **A** Preoperative dental occlusion indicated a Class III anterior open bite with an accentuated maxillary compensating curve; **B** the occlusion was set up as a positive anterior overbite, Class I premolar relation, and large posterior open bite; **C** the 0.014 NiTi leveling wire was inserted 1 day before OGS, light intermaxillary elastics were inserted after OGS, and the anterior occlusion was gradually settled at 6 weeks after surgery; **D** completion of the treatment at 11 months after OGS; **E** CBCT obtained 1 week after surgery; **F** CBCT obtained after completion of the surgical orthodontic treatment.

DISCUSSION

This study was conducted to elucidate the patterns of occlusion design in SFA surgical–orthodontics and their corresponding bony positioning effects in skeletal Class III malocclusions. The case selection criteria, including no or mild crowding, no accentuated curve of Spee, and no remarkable dentoalveolar protrusion, were derived by reviewing the relevant literatures.⁸ To simplify the concerns regarding the effects of dental alignment on the occlusion setup and mandibular movement, only the relative mandibular positions were compared in the simulation scenario.

The SFA involves the prediction of postoperative tooth movements for decompensation, leveling of the curve of Spee, and arch coordination. Therefore, despite dental interferences, some general principles of occlusion planning are similar among different orthodontists, as

demonstrated by the present study. By evaluating the occlusion setups, this study outlined several common strategies for surgical correction of skeletal Class III malocclusion (Table 5). A larger than normal overjet and a Class II canine relationship were preserved for postoperative labial tipping of lower anterior teeth after leveling the curve of Spee and dental decompensation. A Class II molar relationship was set with an expected relapse of the mandibular position after surgery. The amount of mandibular setback in SFA should also consider about the relapse rate of approximately 12%–15%.^{7,12}

A maximal posterior open bite of 5 mm was identified in a patient who had an anterior open bite and an accentuated compensating curve in the maxillary arch before treatment. The open bite was created in the posterior rather than the anterior region in patients with an accentuated compensating curve because achieving bite closure in the molar area is less difficult. With

Table 5. Strategies for occlusion design for using a SFA.

Dimension	Principle
Sagittal	<ul style="list-style-type: none"> • Bilateral symmetric canine and molar relationship • Class II canine, Class I molar, mild Class II molar for expected relapse • Excessive incisor overjet for cases with moderate crowding, retroclined lower incisors
Vertical	<ul style="list-style-type: none"> • Positive anterior overbite • Symmetric posterior occlusal clearance • Mild posterior open bite
Transverse	<ul style="list-style-type: none"> • Near coincident upper and lower midlines unless asymmetric crowding exists • Buccal overjet based on apical base compatibility

sufficient space, posterior open bites can be gradually closed with the aid of the patients' occluding function and vertical elastics. Moreover, after a positive overbite is established, the lower anterior facial height is determined and maintained. Studies have shown that the stability of an anterior open bite corrected by incisor extrusion ranges from 78% to 96%.^{13,14} However, after the anterior open bite relapses, it can severely destroy the esthetics and chewing and speech functions. Figure 4 illustrates one of the clinical examples of closure of a severe posterior open bite after surgery through the SFA. The finishing occlusion in this patient was solid and stable by large molar extrusion. Moreover, the biological mechanism of a posterior extrusion after OGS requires further investigation.

In all study groups, the lower dental midline relative to the MSP showed an undercorrection of approximately 0.5 mm, because most asymmetric cases had canted occlusal planes.¹⁵ By realigning the maxilla through roll rotation, the residual deviation could be completely corrected. Moreover, no direct correlation was observed between the correction of chin deviation and lower midline correction, which may be attributed to the dental interferences that prevent optimal mandibular positioning.

Common dental interferences in the postoperative occlusion setup for the SFA in skeletal Class III malocclusion include malaligned teeth, extruded upper second molars, incompatible arch width, and the accentuated curve of Spee or compensating curve. To eliminate these interferences, the three orthodontists maintained a positive incisor overbite but left the posterior open bite to be corrected after surgery. Thus the distal segment movement tends to have an anterior–upward–posterior–downward rotational pattern. This phenomenon also explains the correlation between the anterior and posterior regions in the VD. The occlusion setup involving a deeper overbite and a greater decrease in the anterior VD (occlusion C) tended to have a greater increase in the posterior open bite and VD (mandible C) and less

mandibular setback. The occlusion setup strategies of the three orthodontists in the present study are completely different from that proposed by Dr. Sugawara, in which the mandibular setback process moves along the functional occlusal plane. This pattern usually leads to an anterior open bite immediately after surgery, which is later corrected using miniplates by intruding the upper molars.^{16,17} This setup strategy prevents an increase in the posterior facial height during surgery. Furthermore, studies have shown that the relapse rate of intruding maxillary molars with a skeletal anchorage system ranges from 20%–30%.^{18–20} By contrast, in our center, an increase in the posterior facial height was solved by performing Le Fort I osteotomy with posterior impaction. This strategy may have flexible amount of mandibular setback and the less risk of impinging airway.²¹

Comparing the skeletal changes in the SFA and SPO groups reveals that the posterior VD variation was the only significantly different variable. Because of the dental interferences that prevent occlusion seating in a close contact, VD significantly increased with the SFA. Furthermore, studies have shown that increasing the posterior facial height might lead to an unstable result from the stretching of the muscle sling.^{22,23} To prevent problems associated with stability, the use of the double-jaw surgery that combines maxillary posterior impaction to control the posterior VD during surgery is justified.²⁴ In addition to VD change, though not statistically significant, less setback amount at Pog in SFA group compared to SPO group was also observed. Due to the “anterior-upward posterior-downward” rotation pattern of the mandible in SFA groups, anterior-posterior position of the anterior mandible was also affected. However, a larger than normal OJ setup in SFA groups, which is one of the common setup principles mentioned in the previous paragraph, modifies the anteroposterior position of the Pog. This may contribute to the insignificance of the result.

The limitations of this study included small sample size and only mandible surgery was simulated to

determine the correlation of the occlusion with the skeletal movement. However, all the study patients had actually received bimaxillary surgeries. The experimental design also prevented us from evaluating the effect of practical surgeries on the whole profile. Moreover, the digital files for virtual preparation were scanned from the models acquired from alginate impressions. Therefore, some inaccuracies and loss of detailed structures were observed. This may produce unobservable collisions during dentition alignment. During arch articulation, unlike in handheld articulation, some interarch penetration may occur. To minimize this problem, the collision threshold was set at a clinically ignorable value of 0.2 mm in the software program. Finally, accurate setup of SPO especially in the vertical direction, was difficult.

The outcomes of the simulation show that when all other conditions remain the same (e.g., surgeon's experience, surgical techniques, and patient conditions), similar occlusion planning with a similar resultant mandibular position could be obtained through the SFA. That is, the strategy of occlusion planning for the SFA can be trained and calibrated. The results of the present study also suggest that similar amounts of mandibular setback and transverse correction can be achieved using the SFA and MPO. A significant difference was observed in only the control of posterior VD, which is more critical with the SFA than with the MPO.

CONCLUSION

Orthodontists with different levels of experience proposed similar occlusion design strategies and were able to manage the SFA surgical orthodontics with compatible simulated outcomes. Surgical orthodontic treatment without any preoperative dental alignment results in an increased VD in the posterior mandible during surgery. However, whether the posterior occlusal settling after orthognathic surgery in patients undergoing the SFA would affect the ultimate facial height and surgical

stability, as well as the mechanism underlying posterior open bite correction, requires further investigation.

Acknowledgments

We express our gratitude to our colleague, Mr. Cheng-Wei Chen, for his assistance in the superimposition and simulation techniques.

REFERENCE

1. Behrman SJ, Behrman DA. Oral surgeons' considerations in surgical orthodontic treatment. *Dent Clin North Am* 1988;32:481-507.
2. Proffit WR, Turvey TA, Phillips C. The hierarchy of stability and predictability in orthognathic surgery with rigid fixation: an update and extension. *Head Face Med* 2007;3:21.
3. Liou EJ, Chen PH, Wang YC, Yu CC, Huang CS, Chen YR. Surgery-first accelerated orthognathic surgery: postoperative rapid orthodontic tooth movement. *J Oral Maxillofac Surg* 2011;69:781-785.
4. Baek SH, Ahn HW, Kwon YH, Choi JY. Surgery-First Approach in Skeletal Class III Malocclusion Treated With 2-Jaw Surgery: Evaluation of Surgical Movement and Postoperative Orthodontic Treatment. *Journal of Craniofacial Surgery* 2010;21:332-338.
5. Wang YC, Ko EW, Huang CS, Chen YR, Takano-Yamamoto T. Comparison of transverse dimensional changes in surgical skeletal Class III patients with and without presurgical orthodontics. *J Oral Maxillofac Surg* 2010;68:1807-1812.
6. Liao YF, Chiu YT, Huang CS, Ko EW, Chen YR. Presurgical orthodontics versus no presurgical orthodontics: treatment outcome of surgical-orthodontic correction for skeletal class III open bite. *Plast Reconstr Surg* 2010;126:2074-2083.
7. Ko EW, Hsu SS, Hsieh HY, Wang YC, Huang CS, Chen YR. Comparison of progressive cephalometric changes and postsurgical stability of skeletal Class III correction with and without presurgical orthodontic

- treatment. *J Oral Maxillofac Surg* 2011;69:1469-1477.
8. Liou EJ, Chen PH, Wang YC, Yu CC, Huang CS, Chen YR. Surgery-first accelerated orthognathic surgery: orthodontic guidelines and setup for model surgery. *J Oral Maxillofac Surg* 2011;69:771-780.
 9. Joh B, Bayome M, Park JH, Park JU, Kim Y, Kook YA. Evaluation of minimal versus conventional presurgical orthodontics in skeletal class III patients treated with two-jaw surgery. *J Oral Maxillofac Surg* 2013;71:1733-1741.
 10. Zhou Y, Li Z, Wang X, Zou B, Zhou Y. Progressive changes in patients with skeletal Class III malocclusion treated by 2-jaw surgery with minimal and conventional presurgical orthodontics: A comparative study. *Am J Orthod Dentofacial Orthop* 2016;149:244-252.
 11. Ricketts RM. A detailed consideration of the line of occlusion. *Angle Orthod* 1978;48:274-282.
 12. Ko EW, Lin SC, Chen YR, Huang CS. Skeletal and dental variables related to the stability of orthognathic surgery in skeletal Class III malocclusion with a surgery-first approach. *J Oral Maxillofac Surg* 2013;71:e215-223.
 13. Kucukkeles N, Acar A, Demirkaya AA, Evrenol B, Enacar A. Cephalometric evaluation of open bite treatment with NiTi arch wires and anterior elastics. *Am J Orthod Dentofacial Orthop* 1999;116:555-562.
 14. Kim YH, Han UK, Lim DD, Serraon ML. Stability of anterior openbite correction with multiloop edgewise archwire therapy: A cephalometric follow-up study. *Am J Orthod Dentofacial Orthop* 2000;118:43-54.
 15. Cheong YW, Lo LJ. Facial asymmetry: etiology, evaluation, and management. *Chang Gung Med J* 2011;34:341-351.
 16. Nanda R. *Esthetics and Biomechanics in Orthodontics Surgery First: The Protocol of Innovative Surgical Orthodontics*: Elsevier Health Sciences; 2012. p. 442-472.
 17. Nagasaka H, Sugawara J, Kawamura H, Nanda R. "Surgery first" skeletal Class III correction using the Skeletal Anchorage System. *J Clin Orthod* 2009;43:97-105.
 18. Sugawara J, Baik UB, Umemori M, Takahashi I, Nagasaka H, Kawamura H et al. Treatment and posttreatment dentoalveolar changes following intrusion of mandibular molars with application of a skeletal anchorage system (SAS) for open bite correction. *Int J Adult Orthodon Orthognath Surg* 2002;17:243-253.
 19. Deguchi T, Kurosaka H, Oikawa H, Kuroda S, Takahashi I, Yamashiro T et al. Comparison of orthodontic treatment outcomes in adults with skeletal open bite between conventional edgewise treatment and implant-anchored orthodontics. *Am J Orthod Dentofacial Orthop* 2011;139:S60-68.
 20. Baek MS, Choi YJ, Yu HS, Lee KJ, Kwak J, Park YC. Long-term stability of anterior open-bite treatment by intrusion of maxillary posterior teeth. *Am J Orthod Dentofacial Orthop* 2010;138:396 e391-399; discussion 396-398.
 21. Chen F, Terada K, Hua Y, Saito I. Effects of bimaxillary surgery and mandibular setback surgery on pharyngeal airway measurements in patients with Class III skeletal deformities. *Am J Orthod Dentofacial Orthop* 2007;131:372-377.
 22. Schendel SA, Epker BN. Results after mandibular advancement surgery: an analysis of 87 cases. *J Oral Surg* 1980;38:265-282.
 23. Proffit WR, Turvey TA, Phillips C. Orthognathic surgery: a hierarchy of stability. *Int J Adult Orthodon Orthognath Surg* 1996;11:191-204.
 24. Proffit WR, Phillips C, Dann Ct, Turvey TA. Stability after surgical-orthodontic correction of skeletal Class III malocclusion. I. Mandibular setback. *Int J Adult Orthodon Orthognath Surg* 1991;6:7-18.